



Colonoscopy Report

Name **SAINT, James (Mr)**
09-Sep-1977 (47y) (Male)

Address **6 Brunswick Place,**
Emsworth, Hampshire,
PO10 7UB

Hospital No. **0034911138**
Procedure Date **06-May-2025 16:20**
EMS Report Id **373857**

MR James Saint
6 Brunswick Place
Emsworth
Hampshire
PO10 7UB

Referral Details

Patient Category **Private/Day Case/Admission**
Referral Date **06-May-2025**
Referral Source **GP Referral**
Registered GP **DOCTOR ER Smiley**
Referring Consultant **DOCTOR Richard Ellis**

Referral Reasons

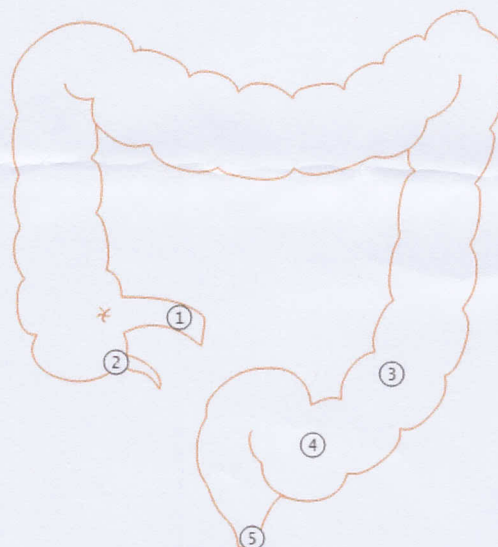
Reasons **Abdominal pain**
Co-morbidities **None**
Current Medication **None**
Preparation **Picolax**
Bowel Prep Quality **Excellent**
Boston Bowel Score **8 (Good)**
ASA Status **ASA I**

Procedure Summary

Endoscopist **Dr Richard Ellis**
Instrument **2202139 (Olympus)**
Medication **2 mg Midazolam**
50 mcg Fentanyl
10 mg Buscopan
Extent of Exam **Terminal ileum**

Findings & Procedures

- 1 - Terminal ileum: (3 images)**
- 2 - Caecum: (1 image)**
- 3 - Proximal sigmoid colon: (4 images)**
- 4 - Distal sigmoid colon: (2 images)**
1 x 6mm, Paris 1s polyp
1 x polyp removed and 1 x retrieved by polypectomy.
Excised en-bloc, cold snare with excision - complete.
Pre-injected with lifting solution
- 5 - Anal margin: (1 image)**
Diverticular disease with a DICA score of 1: Up to 15 (Grade I)
diverticula extending left side of colon with oedema/hyperaemia,
and no complications.



Diagnosis (recorded at procedure)

Diverticulosis, Polyp(s)

Post Pathology Diagnosis

Awaiting Results

Procedure Comments

Sigmoid smooth muscle hypertrophy with diverticula hiding between the folds. One or two areas of mucosal inflammation. These findings are consistent with the ultrasound findings of thickening of the colon wall in the left side of the colon.
One distal sigmoid polyp removed as listed.
Two aphthous ulcers in the terminal ileum of doubtful relevance/significance.
Biopsies from terminal ileum and sigmoid colon.

Patient Management & Follow Up

Can go home and I will arrange a clinic appointment to discuss further and for the results of the histopathology



Colonoscopy Report

Name **SAINT, James (Mr)**
09-Sep-1977 (47y) (Male)

Address **6 Brunswick Place,
Emsworth, Hampshire,
PO10 7UB**

Hospital No. 0034911138
Procedure Date 06-May-2025 16:20
EMS Report Id 373857

Dr Richard Ellis

Consultant Gastroenterologist

Recipients: **Registered GP, Ref. Consultant, Patient, Case Notes**